

# Dark ground microscopy

Vandana Mehta, Kislaya Saurav, C. Balachandran  
Department of Skin and STD, Kasturba Medical College, Manipal, Karnataka, India

## Address for correspondence:

Dr. Vandana Mehta, Department of Skin and STD, Kasturba Medical College, Manipal - 576 104, Karnataka, India.  
E-mail: vandanamht@yahoo.com

## INTRODUCTION

Dark ground microscopy is the most specific and sensitive technique to diagnose syphilis when an active chancre or condyloma lata is present. This technique allows for a presumptive diagnosis of syphilis even before antibodies have developed. Although, unstained living organisms may be observed with an ordinary light microscope, they are seen much more clearly and with a better resolution with a dark ground microscope, which has an optical system that enhances the contrast of unstained bodies.

### Principle of dark ground microscopy<sup>[1,2]</sup>

The dark ground microscope creates a contrast between the object and the surrounding field, such that, the background is dark and the object is bright. The objective and the ocular lenses used in the dark ground microscope are the same as in the ordinary light microscope, however, a special condenser is used, which prevents the transmitted light from directly illuminating the specimen. Only oblique scattered light reaches the specimen and passes onto the lens system causing the object to appear bright against a dark background [Figure 1].

### Requisites for a dark ground microscope<sup>[1,2]</sup>

An ordinary light microscope may be converted to a dark ground microscope by using:

1. A dark ground condenser that focuses only the oblique rays of light onto the specimen.
2. A high intensity lamp.
3. A funnel stop that reduces the aperture of the objective to less than 1.0.

### Procedure for sample collection<sup>[3,4]</sup>

#### A. General

1. Remove any scab or crust covering the lesion.

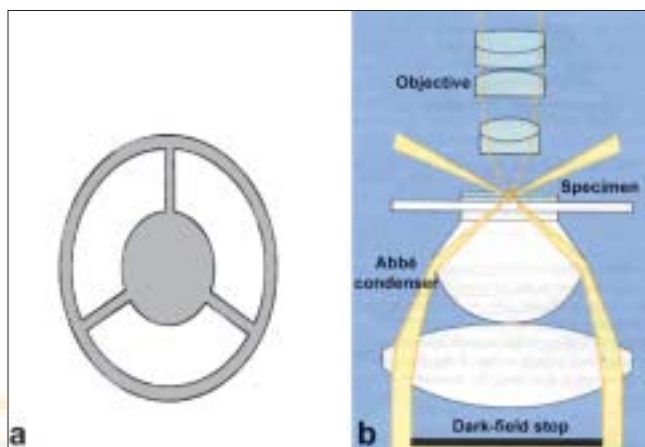


Figure 1: Components of a dark ground microscope: (a) Dark field stop (b) Condenser lens system

2. Remove any exudates with a gauze sponge.
3. Compress base of the lesion to promote accumulation of tissue fluid on the surface.
4. Apply glass slide with a sterile bacterial loop to the surface of the lesion.
5. Press a glass coverslip on the specimen and press it down to remove any air bubbles.
6. Examine the slide immediately.

#### B. Dry, papulosquamous lesions of the skin

1. Gently remove superficial layers of the skin.
2. Compress the lesion if very little fluid appears.
3. Touch a microscopic slide to the lesion.
4. Place a coverslip on the slide and examine.

The simplest way to convert a microscope to dark field microscope is to place (a) a dark field stop underneath (b) the condenser lens system. The condenser then produces a hollow cone of light so that only the light entering the objective comes from the specimen.

#### How to cite this article:

Mehta V, Saurav K, Balachandran C. Dark ground microscopy. Indian J Sex Transm Dis 2008;29:105-6.  
DOI: 10.4103/0253-7184.48739

### Interpretations of dark ground microscopy<sup>[4]</sup>

*Treponema pallidum* appear as brightly illuminated objects against a dark background. They are identified by their typical morphology, size, and movement. *Treponema pallidum* is a 0.25-0.3  $\mu\text{m}$  wide and 6-16  $\mu\text{m}$  long organism with 8-14 regular, tightly wound, deep spirals. It exhibits quick and abrupt movements. The organism rotates slowly along the longitudinal axis (corkscrew motion) accompanied by bending and twisting in the middle.

Other nonsyphilitic spirochaetes (*T. pertenuis* and *T. carateum*) may be loosely coiled, coarse, and thick. Their movement is also different compared to *T. pallidum*, with a more writhing motion, with marked flexion and frequent relaxation of the coils.

False positive results in dark ground microscopy may occur when oral spirochetes are not confirmed or when there is misinterpretation of the characteristic motility of genital spirochetes.

False negative results may be obtained if insufficient exudates are taken, if the interval between sample collection and examination is too long, if the lesion is approaching natural resolution or in patients already on treatment with penicillin.

### Special considerations prior to performing dark ground microscopy<sup>[1,2,5]</sup>

1. The slide should be immaculately clean as any dirt or dust on the slide or on the specimen would shine as brightly as the object itself.
2. Dark ground microscopy is best not performed in the oral cavity. If spirochaetes are seen in the oral cavity, confirmation should be established by immunological means.
3. Whatever be the results of dark ground microscopy, a blood sample should always be taken for serological tests. Three consecutive samples should be examined, before a lesion is considered nonsyphilitic.

### Advantages of dark ground microscopy

The high resolution of a dark ground microscope (0.02  $\mu$ ) allows for easy detection of thin and extremely fragile bacteria as compared to the ordinary light microscope.

### Disadvantages of dark ground microscopy

1. The internal structure of organisms cannot be studied as the light passes around, rather than through the organism.
2. Due to interference from the commensal spirochetes, dark ground microscopy may not be reliable in cases of rectal or nongenital lesions.
3. Risk of HIV transmission from infectious specimens.

### CONCLUSION

The dark ground microscope has proven to be a useful tool in detecting smaller spirochetes such as *Treponema pallidum*, which are so thin that they are practically invisible under an ordinary microscope. The bright contrast of these spirochaetes and their characteristic motility make it easy to detect them under a dark ground microscope, even when they are present in small numbers.

### REFERENCES

1. Isenburg HD. Clinical microbiology procedure handbook. 2<sup>nd</sup> ed. Washington, DC: ASM Press; 2004.
2. Murray PR, Baron EJ, Jorgensen JH. Manual of clinical microbiology. 8<sup>th</sup> ed. Washington, DC: ASM Press; 2003.
3. Lukehart SA, Holmes KK, Fauci AS, Braunwald E, Isselbacher KJ. Harrison's principles of internal medicine. 14<sup>th</sup> ed. McGraw Hill Pub; p.1023-33.
4. Young H. Syphilis: New diagnostic directions. Int J STD AIDS 1992;3:391-413.
5. Larson SA, Hunter EF, Kraus ST. Manual of tests for syphilis. 8<sup>th</sup> ed. Washington, DC: American Public Health Association; 1990.

Source of Support: Nil, Conflict of Interest: None declared.